

# PONY

VOLUME 2, ISSUE 2

Morgan Stanley Children’s Hospital of NewYork-Presbyterian/Columbia University Medical Center

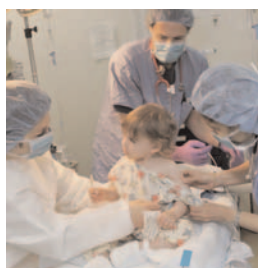## 18-Month-Old Girl Is First in NYC-Area to Receive Titanium Rib Prosthesis That Corrects Severe Spinal Curvature and Gives Lungs Room to Grow

By David P. Roye, Jr., MD and Michael Vitale, MD, MPH

### INSIDE THIS ISSUE

|  |   |
|--|---|
| 18-Month-Old Girl Is First in NYC-Area to Receive Titanium Rib Prosthesis That Corrects Severe Spinal Curvature and Gives Lungs Room to Grow | 1 |
| Selected To National Research Groups   | 1 |
| When Adolescent Idiopathic Scoliosis Requires Surgery  | 2 |
| Proud Parents Donate Their Pride   | 2 |
| Meet Michael Vitale, MD, MPH   | 3 |
| Femur Fractures Most Common in Children  | 3 |
| Nanjing, China Medical Mission   | 4 |

An 18-month-old girl was the first in the New York City area to receive a titanium rib prosthesis to correct a severe form of congenital curvature – or scoliosis – of her spine that constricts the lung cavity. The condition, known as thoracic insufficiency syndrome, prevents the lungs from fully growing, often leading to death in childhood or early adulthood. The successful procedure, recently performed at Morgan Stanley Children’s Hospital of



NewYork-Presbyterian, is part of an ongoing clinical trial of the new device. The recently FDA-approved VEPTR™ (Vertical Expandable Titanium Rib Prosthesis) consists of a telescoping rod with a hook on either end that attaches to the child’s ribs, forcing them apart to open the chest cavity. The device not only expands the chest and allows room for lung growth, but it also straightens the spine, thus correcting scoliosis itself.

CONTINUED ON P.3

## Selected to National Research Groups

Physician–scientists of the Pediatric Orthopaedic Research Group are among an elite group of spine surgeons selected to participate in national research groups. Since its inception five years ago, David P. Roye, Jr. MD and Michael G. Vitale, MD are members of the Chest Wall and Spinal Deformity Study Group. This research committee is comprised of 20 members from across the country who are interested in defining new ways to treat severe deformities that affect both the spine and the rib cage. This group will collect data on the outcomes of patients treated with the

Vertical Expandable Prosthetic Titanium Rib (VEPTR). The efforts of this consortium are supported by Synthes Spine. Dr. Roye is also a member of the Spinal Deformity Study Group, a group of 50 surgeons from across North America. Their focus is collaboration on multicenter studies that allow scientific study of the rare conditions treated by pediatric orthopaedic spine surgeons like congenital scoliosis, infantile and juvenile scoliosis, and scoliosis secondary to syndromes. The extensive data base and logistical support for this group is supported by the Medtronic Corporation.

# When Adolescent Idiopathic Scoliosis Requires Surgery

By David P. Roye, Jr., MD

St. Giles Professor of Pediatric Orthopaedic Surgery

It was no surprise to the Lapes family when their Stony Point, NY pediatrician identified scoliosis in their son Jeff when he was 14 years old. The Lapes family has a strong history of scoliosis. Jeff's mother had surgery for the condition over 20 years ago, and three of their five children required treatment for scoliosis.

Scoliosis can run in families, so a child with a family history of idiopathic scoliosis should be checked regularly for the condition. Surgery may be advised under several circumstances:


“ ... puberty is the time of fastest growth and highest risk... ”

when bracing is not working, when the curve is more than 45 degrees, and when the curve of a growing child is getting worse. Fortunately, the pediatric orthopedists at CHONY use new surgical techniques that make the prospect of surgery much less daunting than it was even a decade ago. Idiopathic scoliosis is relatively common; about three percent of children develop spinal curves that measure over ten degrees. About five percent of those children develop spinal curves that are considered large enough to need treatment – approximately 20 degrees. Puberty is the time of fastest growth, and the time of highest risk for curve progression making timing critical. If surgery is postponed too long, the patient may develop pain, increasing deformity and lung function may be affected. In addition, the surgery becomes more complicated as the curves increase in size. If surgery is done too soon, while the child is still growing, height and flexibility may be compromised. And,

from a psychosocial perspective, surgery can have a significant impact on an adolescent's quality of life.

Jeff's scoliosis progressed quickly. He refused to wear a brace, and refused to alter his grueling dance schedule. He had been dancing since the age of 8 and was performing often and teaching. He did not want to take time off. By the time Jeff was 17, his curve had progressed to 65 degrees, affecting the height of his trunk, and causing pain.

Respecting Jeff's need to maintain his performance schedule, David P. Roye, JR., MD, Chief of Pediatric Orthopaedic Surgery, suggested a surgery schedule that would allow Jeff to fulfill his commitments. Dr. Roye corrected the curve by performing a limited fusion to ensure mobility in Jeff's shoulders, neck and back. Three months after surgery he was performing a break dancing routine, spinning on his head.



Jeff performed a break-dancing routine only three months after scoliosis surgery.

Note: The following Poster will be presented at the 12th IMAST Meeting in Banff, Canada, July 7-9: "Coronal and sagittal plane correction in Adolescent Idiopathic Scoliosis: A Comparison between Thoracic Pedicle Screw and Hook Constructs"

## Proud Parents Donate Their Pride



(L. to R. Hiroko Matsumoto, Research Coordinator; Hosts: Geoffrey and Jennifer Ringelstein; Dr. David P. Roye, Jr., Chief of Pediatric Orthopaedic Surgery, and wife Dr. Carol Roye; Dr. Michael Vitale, Pediatric Orthopaedic Surgeon.)

Geoffrey and Jennifer Ringelstein hosted a party at their Greenwich Village loft apartment that raised over \$8,000 for Pediatric Orthopaedic Research. Their daughter had received surgical care by David P. Roye, Jr., Chief of Pediatric Orthopaedic Surgery when she was an infant,

and they wanted to say thanks in some way. Jennifer Ringelstein remembers, "It was difficult as a new mother to try to hold my

“ ...over \$8,000 for pediatric orthopaedic research... ”

baby because she had to wear an apparatus. The doctors were so understanding, and really helped me through the whole process." With their daughter, now two years old, running around the apartment, Jennifer laughed, "Last month, we were able to watch our daughter win a relay race at her school – she was the fastest runner."

Meet

## Michael Vitale, MD, MPH



**Michael G. Vitale, MD, MPH** has a special interest in complex deformities of the lower extremities including Blounts disease and leg lengthening. His position as Herbert Irving Assistant Professor of Orthopaedic Surgery at Columbia University is based on his concern for

the care and treatment of children with neuromuscular disorders such as cerebral palsy, spina bifida and the muscular dystrophies. His research in this area focuses on ways to optimize the quality of life of these children. Furthermore he has special experience in the treatment of scoliosis in multi-handicapped children as well as

in the treatment of spine problems in young children, starting from birth.

While completing medical school at Columbia, he also earned a Masters in Public Health. Subspecialty Fellowship trained in Pediatric Orthopedics at the Children's Hospital Los Angeles, Dr. Vitale is now Assistant Professor in the Division of Pediatric Orthopaedic Surgery.

Dr. Vitale was recently a featured speaker at the annual CME symposia, taught a spine course in Phoenix, and was just named to the Board of Directors – Orthopaedic Group for the American Academy of Pediatrics.

Dr. Vitale has traveled to Honduras and China as part of a volunteer effort to help children with orthopedic problems, and runs marathons in his spare time.

## Femur Fractures Most Common in Children

By **Michael Vitale, MD, MPH**

*Herbert Irving Assistant Professor of Orthopaedic Surgery*

**F**emur, or thighbone fracture is the most commonly occurring hospitalized traumatic orthopaedic injury in children. While femur fractures represent 21.7% of hospitalized traumatic orthopaedic injuries, the number of tibia/fibula, or leg fractures was not far behind, accounting for 21.5%. Other conditions, such as fractured humerus (upper arm), radius or ulna fracture (lower arm), and vertebral, or spinal fracture, were reported at 17%, 14.7% and 5.2%, respectively.

Pediatric trauma is a leading cause of death and disability

in children. The authors of this study were interested in looking at the variability in care of children's injuries and identifying trends in pediatric trauma. They concluded that orthopaedic surgeons can be instrumental in prevention of recreational orthopaedic injuries by participating in patient education, research and programs that promote safe play.

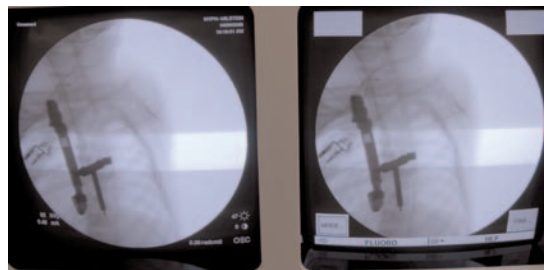
*Note: This study was recently presented by Michael G. Vitale, MD, lead author of the study, at the American Academy of Orthopaedic Surgeons (AAOS) 71st Annual Meeting in San Francisco, Calif. For full text, please contact our offices at (212) 305-5475.*

## 18-Month-Old Girl Is First in NYC-Area to Receive Titanium Rib Prosthesis That Corrects Severe Spinal Curvature and Gives Lungs Room to Grow

(CONTINUED FROM P. 1)

"Parents and pediatricians alike need to be made aware of this important new treatment option – a new paradigm in the treatment of thoracic insufficiency syndrome," says Dr. David P. Roye, director of pediatric orthopedic surgery and Livingston Professor of Pediatric Orthopedics at Columbia University College of Physicians and Surgeons. Traditionally,

thoracic insufficiency syndrome is treated by fusing together vertebrae of the child's spine; however, this treatment prevents the body from growing, and the lungs from fully developing. "Compared to traditional spine surgery, the new procedure is relatively straightforward and recovery is much quicker," explains Dr. Michael Vitale, assistant attending orthopedic



*A telescoping mechanism adjusts with the child's growth.*

surgeon and Herbert Irving Assistant Professor of Pediatric Orthopedic Surgery, who assisted Dr. Roye with the procedure. Every six months, at least until the child is eight-years-old, the telescoping mechanism of the prosthesis is adjusted in order to keep pace with the child's growth. These adjustments continue until the child's chest cavity is sufficiently

large, usually between the ages of eight and fifteen.

"The child hardly notices the installed prosthesis," says Dr. Roye. "They do not need to wear a brace or a cast, and have no restrictions on normal activities." Candidates for the prosthesis range in age from six months to six years. Interested parents may call 212-305-5475.

David P. Roye, Jr., MD  
*Chief*

Francis Y. Lee, MD, PhD

Joshua E. Hyman, MD

Michael G. Vitale, MD, MPH  
*Editor-in-Chief*

Linda Waters, MSN, PNP

Morgan Stanley  
Children's Hospital of  
NewYork-Presbyterian  
Division of  
Pediatric Orthopaedics  
3959 Broadway,  
8th Floor  
New York, NY 10032  
1-212-305-5475

# Nanjing, China Medical Mission

Pediatric orthopaedists Dr. David Roye, and Dr. Joshua Hyman traveled to Nanjing China in May as part of a volunteer surgical team organized by Children of China Pediatrics Foundation (CCPF) to administer care to disabled Chinese orphans.

Over forty children were treated during the one-week visit. Orthopaedic procedures included repair of clubfeet and dislocated hips, straightening deformed legs and muscle surgery to help orphans with cerebral palsy to walk. The team also lectured at two medical schools in Nanjing and provided training sessions.

**Serving the Tri-State area, call : 212-305-4565 for an appointment in any of our locations.**

- New York** ➤ **Manhattan**
- Children's Hospital of NY-Presbyterian, 3959 Broadway at 165th Street
  - Herbert Irving Center, 161 Fort Washington Avenue at 165th Street
  - Columbia Eastside, 16 East 60th Street (*New expanded hours*)
- Brooklyn**
- Sclafani-Vitale Orthopaedics, 9711 Third Avenue
  - Methodist Medical Center, 263 Seventh Avenue
  - Maimonides Medical Center, 1301 57th Street
- Middletown**
- Horton Medical Pavilion, 75 Crystal Run Road
- White Plains**
- Medical Office Park, 244 Westchester Avenue
- New Jersey** ➤ **Edgewater**
- Palisades Medical Arts Building, 968 River Road
- Teaneck**
- Medical Office Building, 699 Teaneck Road
- Connecticut** ➤ **Greenwich**
- Greenwich Hospital, 5 Perryridge Road

**Visit our website [www.childrensorthopaedics.com](http://www.childrensorthopaedics.com)**